



01

CHAPTER

# ANATOMICAL TERMS

مصطلحات تشريحية

TOPICS

## Terminology



Scientific content prepared by

**Booknerd Team**



01092318718

ANATOMY DENT 6 OCTOBER

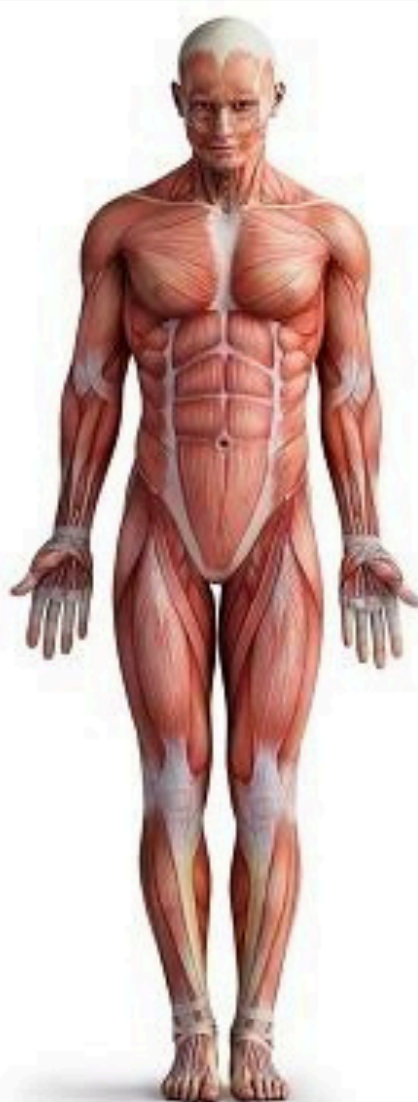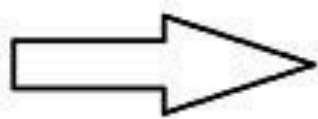






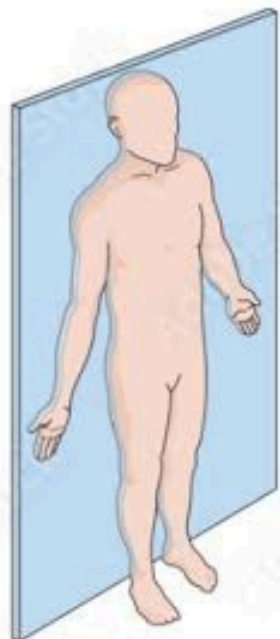
## Anatomical position

The Anatomical Position

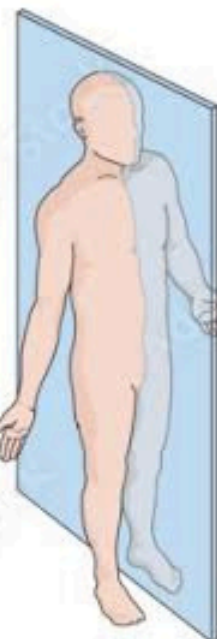

all the anatomical descriptions are **based on a position** in which the man is standing, with his face & palms of hands directed forward & the feet are close to each other.

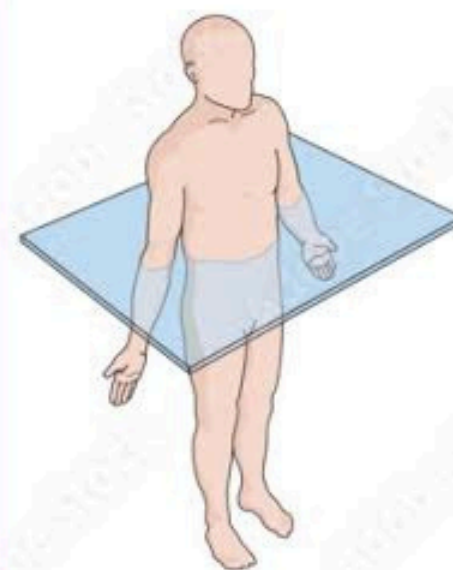
## Anatomical planes & directions:



Frontal (coronal) plane



Sagittal plane



Transverse (horizontal) plane

**Median (sagittal) plane:** a vertical plane which divides the body at the **midline** into Rt & Lt equal halves.

- According to this plane & the planes parallel to it (**paramedian or parasagittal planes**) the body is divided into medial (near the midline) & lateral (away from midline).

**Coronal plane:** a vertical plane which divides the body into anterior (in front of the plane) & posterior (behind the plane).

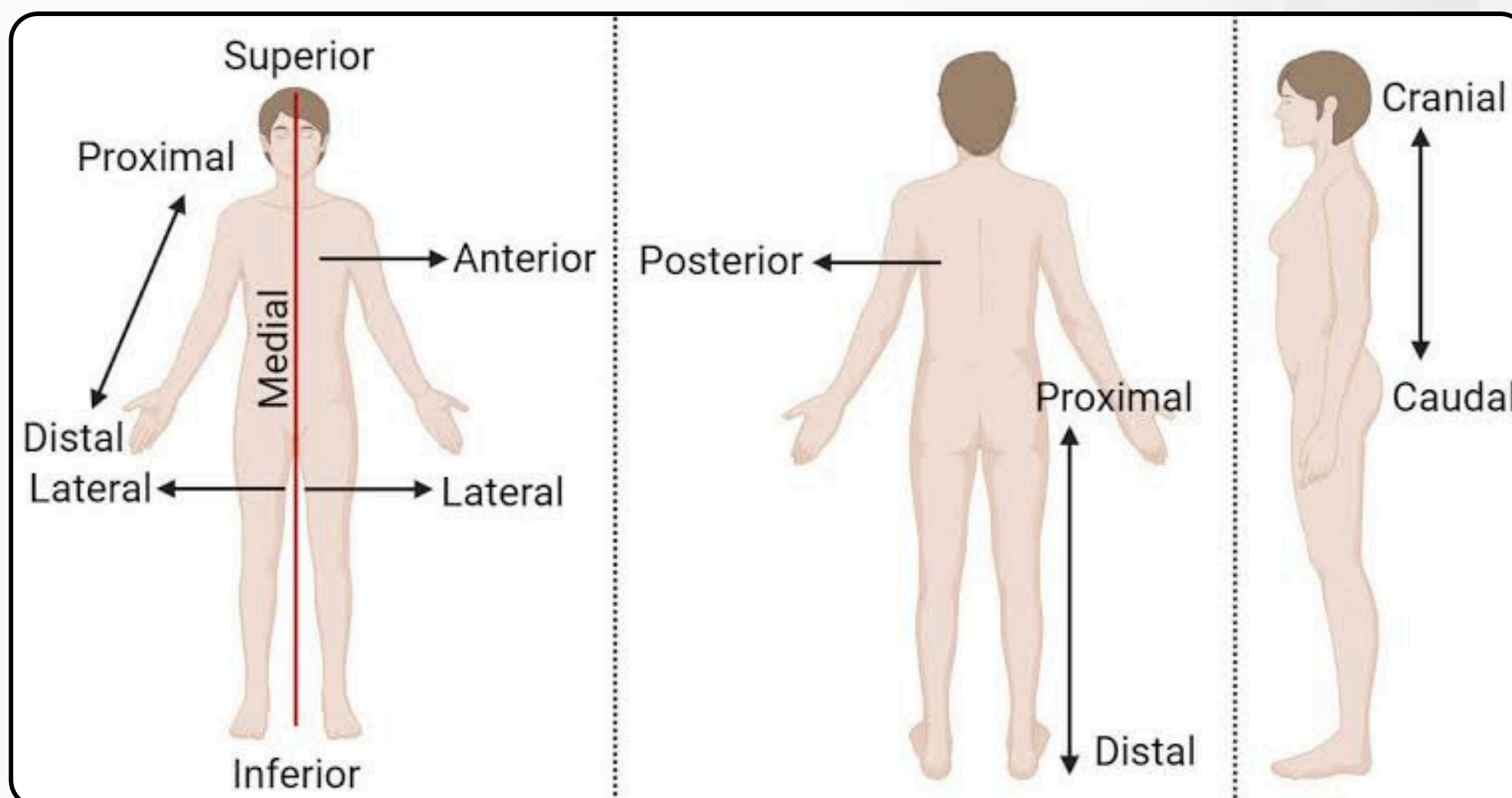
**Transverse (horizontal) plane:** which divides the body into superior (upper) & inferior (lower) parts.







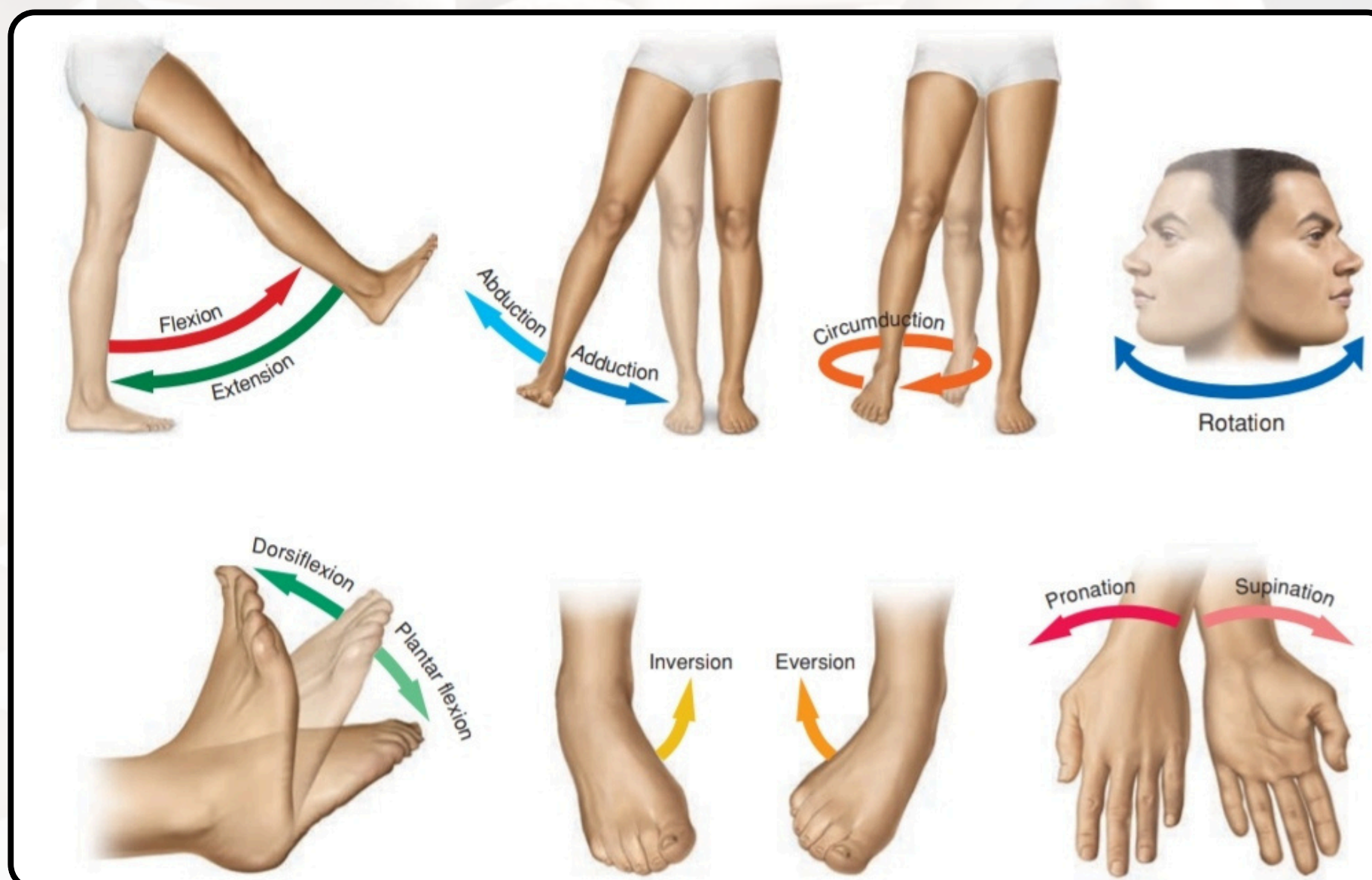
## Anatomical descriptions:



In addition to the previous terms, others could be used as:

- **Superficial & deep:** near or away from the surface.
- **External & internal:** outside or inside.
- **Proximal & distal:** near or away from the trunk.

## Terms of movements:



- **Flexion & extension:** moving 2 ventral surfaces towards or away from each other.
- **Adduction & abduction:** movement towards or away from midline.
- **Medial & lateral rotations:** moving the anterior side towards or away from the midline.



other terms of movements may be **used in specific sites.**

